



Research Article

Healing Amidst the Haze: A Homoeopathic Study of Pollution – Triggered Seasonal Allergies

Dr. Vineeta Neeraj Kumar ^{1*}, Nayak Kirtan Subhash Chandra ², Dr. Archana Srivastava ³,
Verma Anjali Manoj Kumar ⁴, Yadav Rashmi Manoj Kumar ⁵

¹ BHMS, MD (Hom), DNHE, Associate Professor, HOD Department of Surgery, Aarihant Homoeopathic Medical College & Research Institute, Swarnim Startup and Innovation University, Bhoyan Rathod, Near ONGC WSS, Adalaj Kalol Highway, Gandhinagar, Gujarat, India

² BHMS, Aarihant Homoeopathic Medical College & Research Institute, Swarnim Startup and Innovation University, Bhoyan Rathod, Near ONGC WSS, Adalaj, Kalol Highway, Gandhinagar, Gujarat, India

³ BHMS, MD (HOM), Associate Professor, HOD Department of Homoeopathic Pharmacy, Chandola Homoeopathic Medical BHMS, MD (HOM) College, Rudrapur, Uttarakhand, India

⁴ BHMS, Aarihant Homoeopathic Medical College & Research Institute, Swarnim Startup and Innovation University, Bhoyan Rathod, Near ONGC WSS, Adalaj Kalol Highway, Gandhinagar, Gujarat, India

⁵ BHMS, Aarihant Homoeopathic Medical College & Research Institute, Swarnim Startup and Innovation University, Bhoyan Rathod, Near ONGC WSS, Adalaj Kalol Highway, Gandhinagar, Gujarat, India

Corresponding Author: * Dr. Vineeta Neeraj Kumar

DOI: <https://doi.org/10.5281/zenodo.21160366>

Abstract

Seasonal allergic conditions like allergic rhinitis, bronchial asthma, and allergic conjunctivitis are prevalent in urban areas of India, where increasing air pollution significantly contributes to triggering and aggravating symptoms. Contact with pollutants such as particulate matter (PM2.5, PM10), nitrogen oxides, sulfur dioxide, and emissions from vehicles intensifies seasonal allergies during certain times of the year. Allergic Rhinitis is a prevalent inflammatory condition increasingly observed in Urban populations, largely due to rising air pollution and environmental allergens.

Conventional treatment offers symptomatic relief but is often associated with recurrence and potential side effects.

Manuscript Information

- ISSN No: 2583-7397
- Received: 18-05-2026
- Accepted: 27-06-2026
- Published: 03-05-2026
- IJCRM:5(4); 2026: 21-28
- ©2026, All Rights Reserved
- Plagiarism Checked: Yes
- Peer Review Process: Yes

How to Cite this Article

Kumar V N, Chandra N K S, Srivastava A, Kumar V A M, Kumar Y R M. Healing Amidst the Haze: A Homoeopathic Study of Pollution – Triggered Seasonal Allergies. Int J Contemp Res Multidiscip. 2026;5(4):21-28.

Access this Article Online



www.multiarticlesjournal.com

KEYWORDS: Allergic Rhinitis, Homoeopathy, Air Pollution, Seasonal Allergies, Respiratory Health.

1. INTRODUCTION

WHAT IS ALLERGIC RHINITIS?

Allergic Rhinitis is an IgE-mediated inflammatory disorder of the nasal mucosa caused by exposure to allergens, leading to symptoms like sneezing, nasal discharge, itching & congestion.

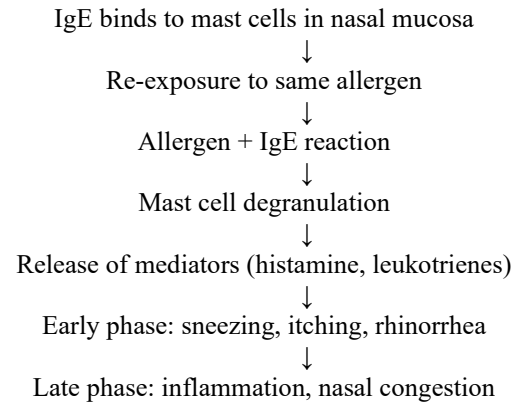
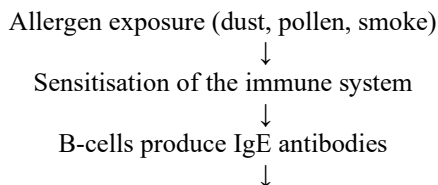
Aetiology

Environmental Allergens: Pollen, Dust mites, Molds, Animal dander

Air Pollutants:

1. **Particulate Matter (PM2.5 and PM10):** Ultra-fine dust particles that enter your lungs and bloodstream, leading to inflammation and respiratory distress.
2. **Vehicle emissions:** Nitrogen dioxide and carbon monoxide can inflame airways, worsen asthma, and trigger allergic reactions.
3. **Industrial smoke and smog:** These release toxic pollutants like sulfur dioxide and volatile organic compounds, irritating the eyes, nose, and throat.
4. **Construction dust and open burning:** Dust from construction sites and smoke from burning waste can carry allergens that aggravate respiratory allergies. (burning fields).
5. **Toxic gases and chemical fumes:** Exposure to formaldehyde, benzene, and other fumes from household cleaners, paints, or factories can trigger allergic symptoms and skin irritation.
6. **Burning fields:** release pollutants that often trigger allergic reactions.

Pathogenesis



Prevalence:

- In India, prevalence ranges from 20-30%, or roughly 1 in 6 people.
- Prevalence peaks between ages **20–40**.
- Higher in urban areas, linked to pollution and particulate matter (e.g., PM_{2.5}).

AIM:

- To assess the scope of homoeopathic medicine in cases of allergic rhinitis.

OBJECTIVE:

- To study the prevalence of seasonal allergic disorders triggered by air pollution in urban populations.
- To assess the effectiveness of acute homoeopathic remedies in symptom relief.
- To evaluate constitutional prescribing in reducing allergic recurrences.
- To minimize dependency on conventional antiallergic drugs.
- To provide evidence-based support for integrating homoeopathy into public health strategies for pollution-related allergies

2. MATERIALS AND METHODOLOGY

SOURCE OF DATA	Clinical observational study
INCLUSIVE CATEGORIES	1. Patients with a clinical diagnosis of seasonal allergic rhinitis and asthma. 2. History of worsening symptoms during high pollution or seasonal change. 3. Willingness to participate and provide consent
EXCLUSIVE CATEGORIES	1. Patients with life-threatening respiratory diseases (e.g., COPD, severe asthma). 2. Patients on long-term immunosuppressive therapy. 3. Patients unwilling to continue follow-up.

DURATION OF STUDY	5 MONTHS
NO. OF PARTICIPANTS	30

3. OBSERVATION

- Allergic rhinitis was found to be more common in urban populations, likely due to increased exposure to pollutants and allergens.

- The most affected age group was adolescents and young adults, indicating higher susceptibility in this period.
- Common presenting symptoms observed were sneezing, nasal discharge, nasal obstruction, and itching.

4. RESULT

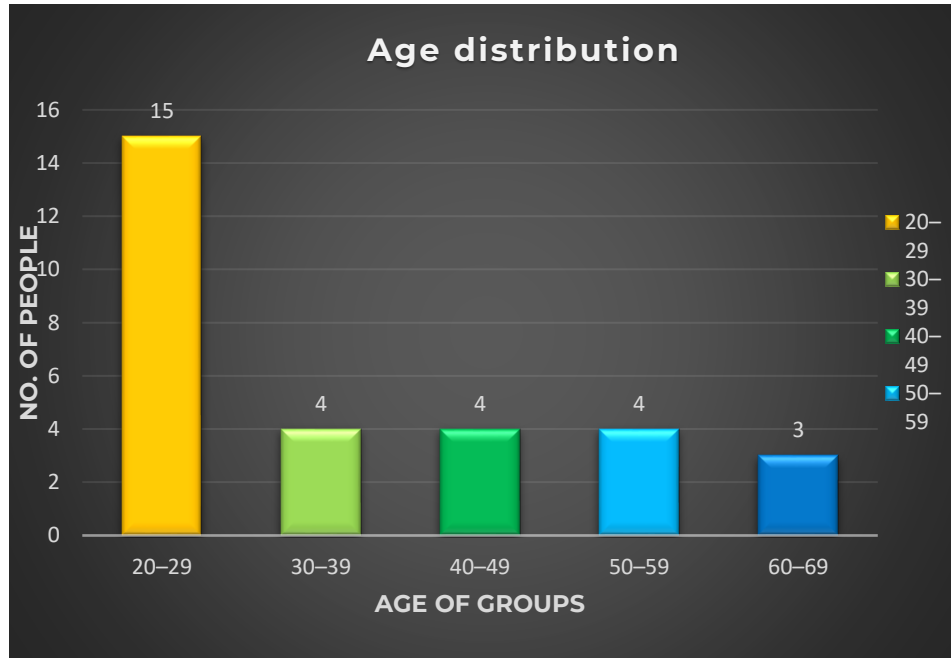


Figure 1: Age Distribution of Study Participants by Decade A bar chart depicting the frequency distribution of study participants (n = 30) across five age groups, spanning from 20 to 69 years. The 20–29-year age group represented the largest proportion of the cohort (n = 15, 50%), followed by equal representation in the 30–39, 40–49, and 50–59 age groups (n = 4 each, 13.3%), with the 60–69 age group constituting the smallest subset (n = 3, 10%). The x-axis represents age groups (years) and the y-axis represents the absolute number of participants per group.

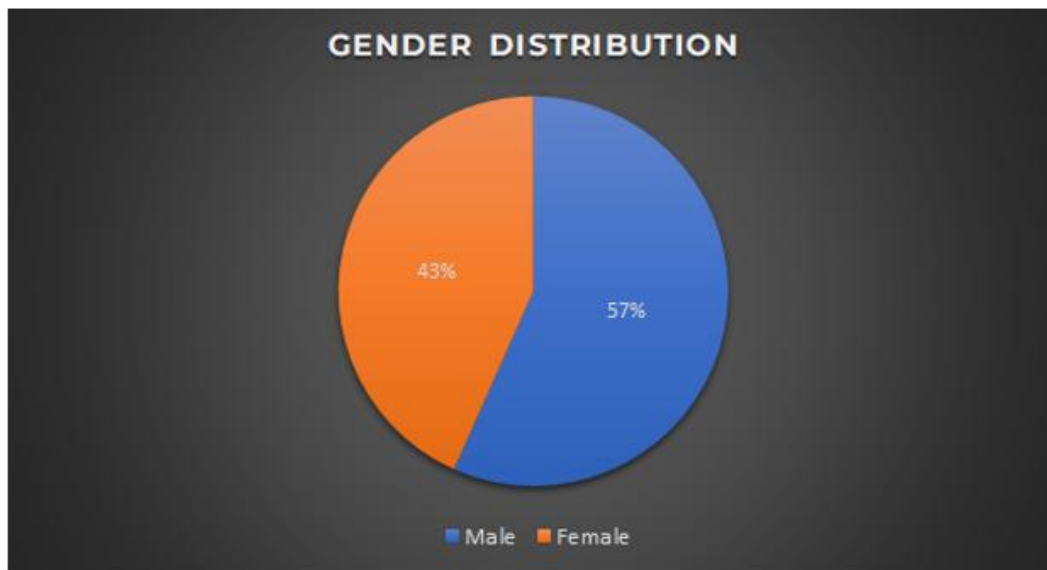


Figure 2: Gender Distribution of Study Participants A pie chart illustrating the gender composition of the study cohort (n = 30). The majority of participants were male (57%, n = 17), while female participants constituted 43% of the sample (n = 13). Data are expressed as percentages of the total study population.

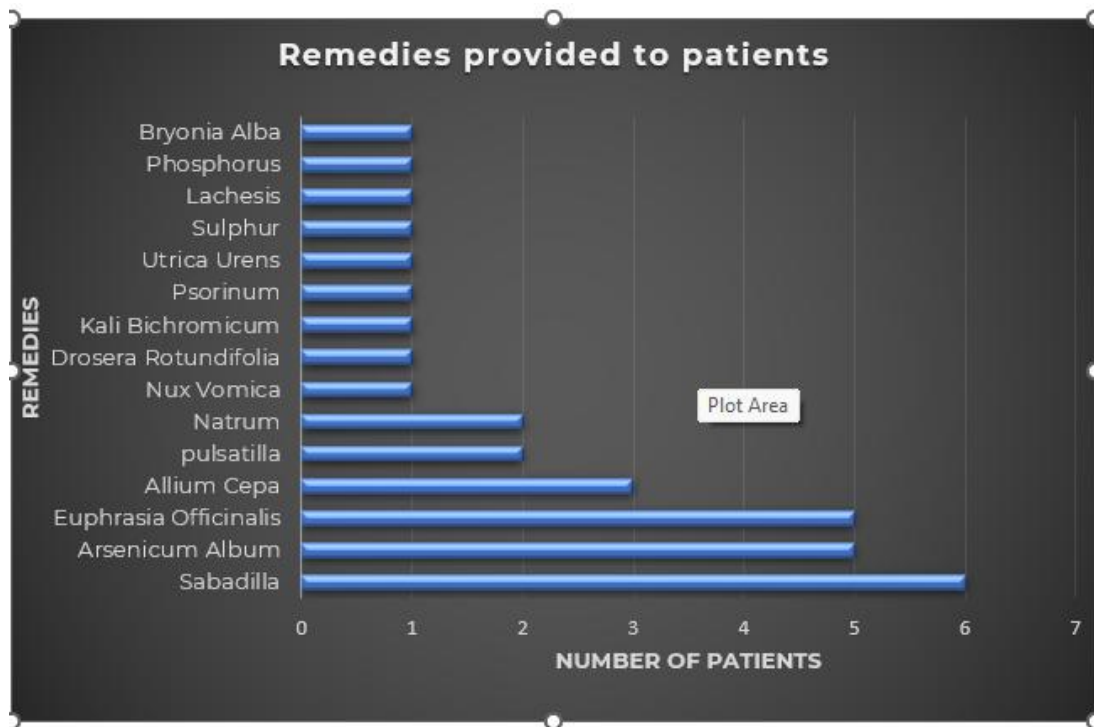


Figure 3: Frequency of Homeopathic Remedies Prescribed to Study Participants A horizontal bar chart representing the distribution of homeopathic remedies administered across the study cohort (n = 30). A total of 10 distinct remedies were recorded. *Sabadilla* was the most frequently prescribed remedy (n = 6), followed by *Euphrasia officinalis* (n = 5) and *Allium cepa* (n = 3). *Pulsatilla* was prescribed to 2 participants, while *Nux vomica*, *Kali bichromicum*, *Urtica urens*, *Lachesis*, and *Bryonia alba* were each administered to a single participant (n = 1). The x-axis denotes the number of patients and the y-axis lists the remedies in ascending order of prescription frequency

MASTER CHART									
Sr. No.	Name	Age	Gender	Presenting Complaints	Past History	Family History	Diagnosi s	Remedy with Potency	Result
1	A	47	F	frequent sneezing, especially in morning, profuse watery in nasal discharge. Marked watering eyes. Burning sensation in eye, redness of conjunctiva. Symptoms worse during spring season and exposure to dust.			Allergic Rhinitis	Euphrasia Officinalis 200P	Marked improvement
2	B	53	F	frequent sneezing especially in morning porfuse watery in nasal discharge. Marked watering eyes. Burning sensation in eye, redness of conjunctiva. Symptoms worse during spring season and exposure to dust.			Allergic Rhinitis	Euphrasia Officinalis 200P	
3	C	60	M	frequent sneezing especially in morning porfuse watery in nasal discharge. Marked watering eyes. Burning sensation in eye, redness of conjunctiva. Symptoms worse during spring season and exposure to dust.			Allergic Rhinitis	Euphrasia Officinalis 200P	Marked improvement
4	D	40	M	frequent sneezing especially in morning porfuse watery in nasal discharge. Marked watering eyes. Burning sensation in eye, redness of conjunctiva. Symptoms			Allergic Rhinitis	Euphrasia Officinalis 200P	Moderate Improvement

				worse during spring season and exposure to dust.						
5	E	40	F	Watery discharge for nose with Itching and Burning in eyes for 3-4 days due to dust particles	IHD	-	Allergic Rhinitis	Sabadilla 200P	Moderate Improvement	
6	F	55	M	Watery discharge from nose for 3 days aggravate by warm room ameliorate by cold weather	Hypertension	-	Allergic Rhinitis	Pulsatilla Nigricans 200P	Marked improvement	
7	G	42	M	Watery discharge for nose with Itching and Burning in eyes for 3-4 days due to dust particles	-	-	Allergic Rhinitis	Sabadilla 200P	Marked improvement	
8	H	35	M	Watery discharge for nose with Itching and Burning in eyes for 3-4 days due to sneezing and mild fever.	-	-	Allergic Rhinitis	Allium Cepa 200P	Marked improvement	
9	I	21	F	Watery discharge for nose with Itching and Burning in eyes for 3-4 days due to sneezing and mild fever.	-	-	Allergic Rhinitis	Sabadilla 200P	Marked improvement	
10	J	57	M	Recurrent allergic sneezing for 2 years Dry, irritating cough with throat tickling Coryza with scanty watery discharge Nasal irritation and itching Cough aggravated after exposure to dust, smoke, and pollution Continuous coughing episodes at night Sensation of constriction in throat Hoarseness of voice occasionally	-	-	Allergic rhinitis	Drosera Rotundifolia 30C	Moderate Improvement	
11	K	23	M	Paroxysmal sneezing, especially in the morning profuse watery nasal discharge, burning in nose and eyes and lacrimation with redness. Aggravation by dust, smoke and traffic pollution amelioration warm room	Recurrent episodes of cold and coryza since childhood history of frequent upper respiratory tract infections (URTI)		Allergic Rhinitis	Aleum cepa 200P	Marked improvement	
12	L	22	M	Red itching eyes profuse watery discharge and burning sensation aggravate sunlight and dust exposure and outdoors activity in polluted areas. Amelioration: cold application	Recurrent eye allergies during seasonal changes History of dust sensitivity since childhood		Allergic Rhinitis	Euphrasia officinalis 200P	Marked improvement	
13	M	23	M	Patient presents with recurrent bouts of violent, paroxysmal sneezing accompanied by profuse, watery nasal discharge (coryza) and bilateral acrid lacrimation. Symptoms are	History of bronchial allergy since 15-16 years Repeated episodes of cough and		Allergic Rhinitis	Sabadilla 30C	Moderate Improvement	

				characteristically aggravated upon exposure to particulate matter (dust) and open-air riding on a two-wheeled vehicle, suggesting a strong correlation with inhalation of environmental allergens and cold draft.	wheezing, especially in winter					
14	N	23	F	Dry cough with wheezing and breathlessness on exertion tightness in the chest aggravate exposure to the vehicle smoke and industrial pollution and especially at night at 2-4 AM.	History of bronchial asthma since 5-6 years Repeated episodes of cough and wheezing, especially in winter		Allergic Rhinitis	Arsenicum album 200P	Marked improvement	
15	O	20	M	Dryness of nose with frequent sneezing, Nasal obstruction at night, Loss of smell < Dust, pollution, cold air < Night Amreliation: Warm drinks	Recurrent cold with nasal blockage since 2 years. Frequent use of nasal decongestants		Allergic Rhinitis	Nux Vomica 30C	Marked improvement	
16	P	25	M	Wheezing with cough, Difficulty in breathing, Tight chest < Dust, smoke, pollution < Early morning Amerliation:-Open air	Asthma since childhood Family history of asthma On bronchodilators		Allergic Rhinitis	Natrum sulphuricum 200P	Moderate Improvement	
17	Q	28	M	Sneezing with watery nasal discharge, Itchy, red eyes, Occasional skin rashes < Dust, traffic pollution < Spring season Amerliation:-Indoors	Multiple allergies since childhood Family history of allergic disorders Long-term antihistamine use		Allergic Rhinitis	Psorinum 200C single dose	Marked improvement	
18	R	24	F	Itching eruption (hives) redness with burning sensation and sudden appearance after outdoor exposure aggravated heating pollution sweating and especially in evening. Amreliation by cold application.	History of recurrent urticaria for 1-2 years Episodes triggered by environmental factors (dust, pollution, heat)		Allergic Rhinitis	Utrica urens 30C	Moderate Improvement	
19	S	23	F	Thick yellow nasal discharge,Pain in maxillary sinus region,Post-nasal drip < Cold weather, pollution exposure < Morning Amelioration: Warm applications	Chronic sinusitis for 3-4 years Repeated antibiotic courses		Allergic Rhinitis	Kali bichromicum 30C	Marked improvement	
20	T	20	M	Violent, spasmodic sneezing (one after another), Profuse watery nasal discharge, Tickling in nose < Strong odors, dust, pollen < Cold air Amerliation:-Warm room	Recurrent seasonal allergy since childhood Sensitive to smell		Allergic Rhinitis	Sabadila 200P single dose	Marked improvement	
21	U	55	M	Sudden sneezing (20-30			Allergic	Arsenicum	Marked	

				times in succession), Profuse, watery, acrid nasal dischargem burning is nostrils. Marked itchingof palate Lacrimation (bland) headache from sneezing aggravation - Exposure to pollen/flowers open fields and gardens, morning (on waking) amelioration: Evening time complaints present since 5-7 years and return in every year in feb to march.			Rhinitis	Album 200P	improvement
22	V	23	F	Red, inflamed skin with itching, Burning sensation after scratching, Dry, rough patches < Pollution, cosmetics, heat < Evening Amerliation:-Cold applications	Recurrent skin allergy episodes History of eczema in childhood		Allergic Rhinitis	Sulphur 200C single dose	Marked improvement
23	W	60	F	Red itching eruption on both forearms and neck present for 6 months reccurent worse during spring and after exposure to dust eruptions are: red dry and scanty intense itching especially at night. Scratching causes burning sensations slightly oozing dries into thin crust amel by warmth			Allergic Rhinitis	Arsenicum Album 200P	Marked improvement
24	X	26	M	Patient having complaint watery discharge from nose which lasts for 2-4 days then become thick whitish discharge causes blockage of nose sneezing++loss of smell sometimes. Pateint having dust allergy this type of episodes arise after exposure to dust aggravated by sun, heat, warm room, amel by cold, open air			Allergic Rhinitis	Naturm Muriaticum 200P Saclac 30P	Moderate Improvement
25	Y	35	F	Patient having complaint of frequent sneezing with running nose thin watery nasal discharge and itching in th eyes and nose since last 5 years. Aggravated by damp and rainy weather cold air, cold drinks, dust, smoke, and relive by warm room and steam inhalation.	Bronchial asthma 6 years back	mother hypothyroidis m and osteomyisit	Allergic Rhinitis	sabdila 30C	Marked improvement
26	Z	32	M	Patient having allergic rhinitis thin watery discharge from nose sneezing and having cough but occasionally and patient is heat intolerance aggravated by pollen and dust. Vericos vein and greenish discoloration	Deep vein thrombosis with pulmonary embolism	father COPD mother HIN and asthma	Allergic Rhinitis	Lachesis 0/2 IP H.S. weekly to daily	Marked improvement
27	AA	23	F	Dry, hacking cough, Constant tickling in throat, Hoarseness of voice < Talking, cold air, pollution < Night Amerliation:-Warm drinks	Recurrent laryngitis Exposure to polluted workplace		Allergic Rhinitis	Phosphorous 30C	Moderate Improvement
28	AB	23	F	Thick, greenish nasal	Chronic sinus		Allergic	Pulsatilla	Moderate

				discharge, Nasal blockage, Loss of smell < Cold, pollution, morning Amerliation:-Warm steam	complaints Repeated infections		Rhinitis	30C	Improvement
29	AC	27	F	Dry cough with burning in chest, Difficulty breathing in polluted areas, Scanty expectoration < Smoke, dust, pollution < Evening Amerliation:-Rest	Recurrent bronchitis History of smoking		Allergic Rhinitis	Bryonia alba 30C	Marked improvement
30	AD	34	M	Profuse watery nasal discharge causing burning of upper lip, Frequent sneezing with irritation in nose, Nasal obstruction alternating with discharge < Dust, smoke, air pollution < Midnight (worse after 12 AM) < Cold air Amerliation: Warm drinks, warm covering	Recurrent allergic rhinitis for 4-5 years Frequent use of antihistamines History of weakness after acute episodes		Allergic Rhinitis	Arsenicum album 30C	Marked improvement

5. CONCLUSION

The observations in this study suggest that homoeopathic treatment may play a useful role in managing allergic rhinitis. Unlike conventional medicines that mainly give temporary relief by reducing allergic reactions, homoeopathy aims to treat the individual as a whole and improve the body's natural resistance.


Homoeopathic medicines can be considered a cost-effective and supportive approach for patients suffering from respiratory allergies. The results seen in this study are encouraging, but further detailed studies with larger numbers of patients are needed to better understand and confirm the role of homoeopathy in allergic rhinitis. Treating the patient according

to individual symptoms and constitution may help provide more long-term relief in chronic cases of allergic rhinitis.

REFERENCES

1. Sinha B, Vibha, Singla R, Chowdhury R. Allergic rhinitis: a neglected disease—a community-based assessment among adults in Delhi. *J Postgrad Med.* 2015;61(3):169-75. doi:10.4103/0022-3859.159418.
2. Jain S. A crystal clear picture of age and gender specific incidence of severe persistent allergic rhinitis and triggers of allergic rhinitis in Central India. *Indian J Otolaryngol Head Neck Surg.* 2024;76(6):5746-9. doi:10.1007/s12070-024-05084-x.
3. Periera CD, Warad V, Rodrigues JP, Pandit GS, Gupte V, Thakur GK, et al. An Indian cross-sectional study to evaluate in-clinic allergic rhinitis prevalence in patients having nasal symptoms using the SFAR questionnaire. *J Asthma Allergy.* 2025; 18:1239-51. doi:10.2147/JAA.S516448.
4. Singh S, Sharma BB, Salvi S, Chhatwal J, Jain KC, Kumar L, et al. Allergic rhinitis, rhinoconjunctivitis, and eczema: prevalence and associated factors in children. *Clin Respir J.* 2018;12(2):547-56. doi:10.1111/crj.12561.
5. *Journal of Contemporary Clinical Practice.* 2025. doi:10.61336/jccp.

6. Davidson S, Ralston SH, Penman ID, Strachan MWJ, editors. *Davidson's Principles and Practice of Medicine.* Elsevier; latest edition.
7. Dr Batra's. Pollution allergy symptoms: signs you shouldn't ignore. 2026 May 2. Available from: <https://www.drbatras.com/blog/allergy/does-air-quality-affect-your-allergic-rhinitis>
8. Krishna MT, Mahesh PA, Vedanthan P, Moitra S, Mehta V, Christopher DJ. An appraisal of allergic disorders in India and an urgent call for action. *World Allergy Organ J.* 2020;13(7):100446. doi: 10.1016/j.waojou.2020.100446.

Creative Commons (CC) License	
This article is an open-access article distributed under the terms and conditions of the Creative Commons Attribution–Non-Commercial–No Derivatives 4.0 International (CC BY-NC-ND 4.0) license. This license permits sharing and redistribution of the article in any medium or format for non-commercial purposes only, provided that appropriate credit is given to the original author(s) and source. No modifications, adaptations, or derivative works are permitted under this license.	
About the Corresponding Author	
	Dr. Vineeta Neeraj Kumar is an Associate Professor and Head of the Department of Surgery at Aarohant Homoeopathic Medical College & Research Institute, Swarnim Startup and Innovation University, Gandhinagar, Gujarat, India. She holds BHMS, MD (Hom), and DNHE qualifications. Her interests include homoeopathic surgery, medical education, clinical research, and integrative healthcare.